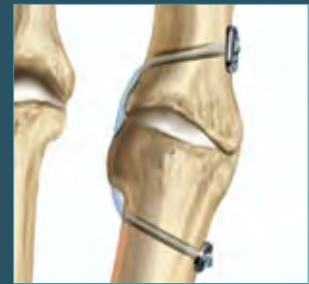
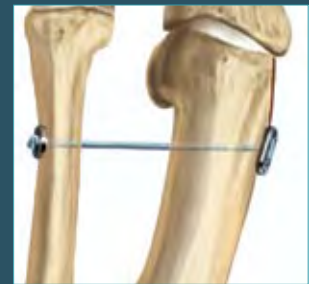
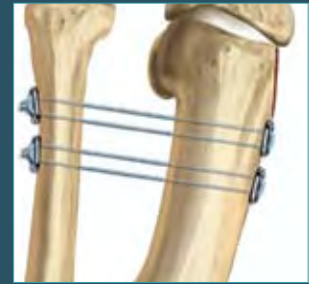
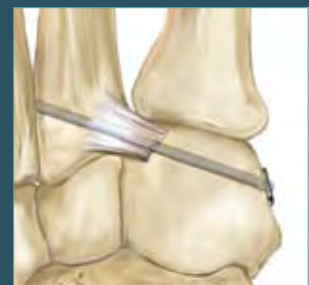
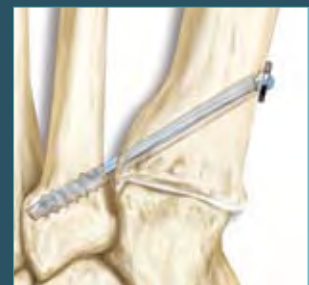Comprehensive Solutions for Forefoot and Midfoot Surgery using the Mini TightRope® System



Five Surgical Techniques



Hallux Valgus Repair

The treatment of hallux valgus deformity includes the assessment of the hallux valgus angle, the intermetatarsal angle (IM angle) and the contribution of an interphalangeus deformity. Additionally, there must be an assessment of the presence or absence of arthritic involvement of both the first metatarsocuneiform joint and the first metatarsophalangeal joint. Other considerations are the orientation of the distal metatarsal articular angle and the orientation and stability of the first metatarsocuneiform joint.

Various methods have been described to correct the intermetatarsal angle. Soft tissue correction can be achieved by suturing the lateral capsule of the first metatarsal to the medial capsule of the second metatarsal, incorporating the intervening, previously released adductor tendon. A loss of reduction can occur due to the forces that oppose the suture repair, as well as the possibility that poor tissue quality can contribute to a loss of reduction.

In the presence of more rigid deformities, the IM angle is reduced by using a distal or proximal osteotomy of the first metatarsal. Such osteotomies can be technically challenging. A rather daunting list of consequences and potential complications include delayed union, malunion, nonunion, excessive shortening of the first metatarsal, avascular necrosis, hardware failure and prolonged protected ambulation.

The Mini TightRope is useful as an alternative and adjunct method for reduction of the IM angle. A FiberWire® and button construct (distal approach) or FiberWire and anchor construct (proximal) are placed across the first and second metatarsals. As the FiberWire is tightened, the IM angle is reduced to a normal value (less than 9-11°). Using the button or anchor construct, the suture is tied over the button, maintaining a secure reduction of the IM angle. Used alone or in conjunction with the distal soft tissue intermetatarsal repair (distal approach), this technique affords a greater degree of strength and security than can be achieved with the soft tissue repair alone.

Hallux Varus Repair

Hallux varus is most often seen as a complication of bunion surgery, but can be related to other conditions as well. To date, the procedures described to correct the deformity involve transfer of either a portion or all the extensor hallucis longus or brevis tendons. These procedures often leave some deficit in extensor function and can necessitate more incisions in addition to those used to perform the original procedure. The use of the Mini TightRope to correct hallux varus does not sacrifice tendons, can be done through two small incisions and is a more isometric reconstruction of the lateral structures of the first metatarsophalangeal joint.

Mini TightRope FT Fixation

The Mini TightRope FT was developed to offer surgeons a new technique for the correction of the IM angle for hallux valgus. As is with the standard Mini TightRope placed distally, the Mini TightRope FT can support correction of the IM angle if used proximally along the 1st metatarsal. The Mini TightRope FT utilizes a 4.5 mm (fully threaded) Bio-Corkscrew® FT, #2 FiberWire and a cupped stainless steel button. The proximally placed anchor/suture button construct will support reduction of the IM angle while allowing soft tissue remodeling and stabilization.

Lisfranc Ligament Repair

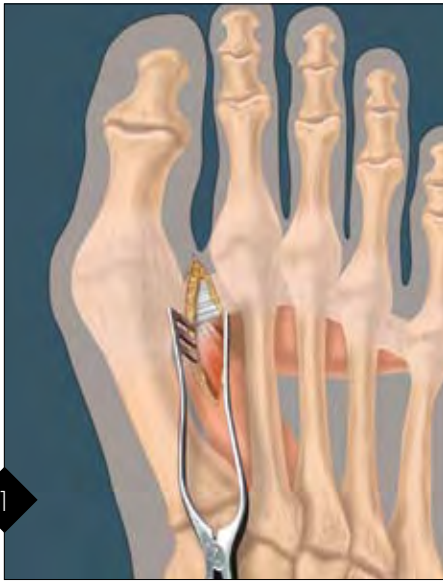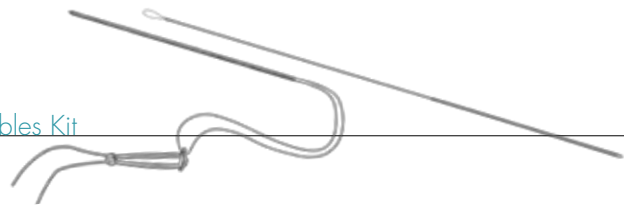
The successful treatment of Lisfranc joint injuries includes the achievement and maintenance of an anatomic reduction. The failure to achieve an anatomic reduction, a failure of fixation or a failure to maintain proper postoperative immobilization can contribute to an unsuccessful outcome.

An early method of fixation involved the use of smooth pins or Kirschner wires. More recently, screw fixation has gained in popularity. The advantages of pin fixation include the relative ease of pin placement along with minimal injury to the articular surfaces. However, pin fixation lacks rigid fixation and usually necessitates a second procedure to remove the pins. There is also the risk of pin tract infection with protruding pins, as well as the risk of pin breakage.

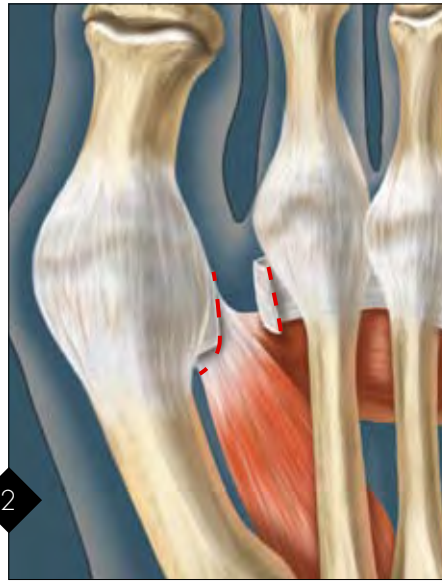
Screw fixation has the advantages of rigid fixation, no protruding hardware and a lower risk of hardware failure. Possibly the major disadvantage of screw fixation is the placement of a screw across articular surfaces of the Lisfranc joints will certainly predispose those joints to the development of posttraumatic arthritis.

The Mini TightRope provides an alternative to both pin and screw fixation. The advantages include: 1) an absence of protruding hardware, 2) a second procedure is not required for its removal, and 3) far less joint disruption than that caused by a 3.5, 4, 4.5, 6.5 or 7.3 mm screw. For more complex fractures this technique can easily be combined with other fixation techniques. The Mini TightRope provides a new approach to treatment of Lisfranc ligament disruptions.

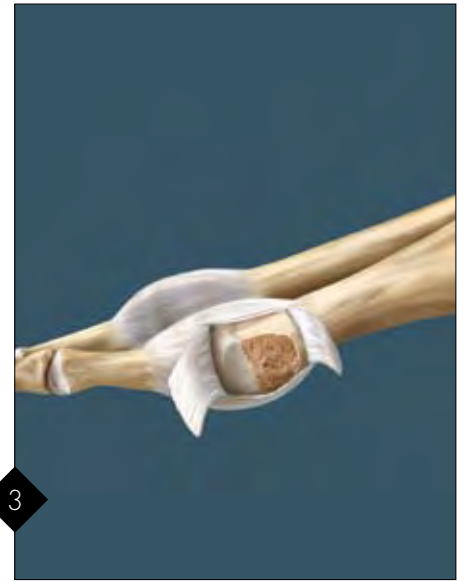Hallux Valgus Repair Mini TightRope® 1.1 mm Disposables Kit



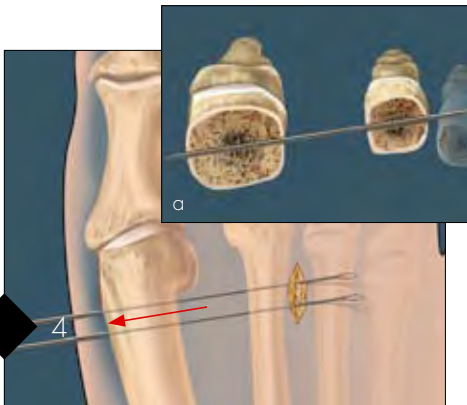
1 For the distal approach, the first interspace release is performed through the incision made between the distal 1st and 2nd metatarsals. A dorsal medial or medial incision can also be used with appropriate distraction of soft tissues.



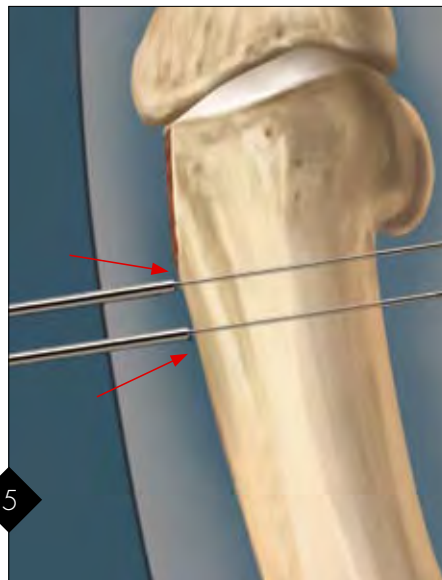
2 To realign the fibular sesamoid, detach the adductor tendon from both the base of the proximal phalanx and the fibular sesamoid. Release the deep intermetatarsal ligament and lateral capsule. Free any sesamoid adhesions to the intermetatarsal ligament. Manually test the reduction of the IM angle following complete soft tissue release.



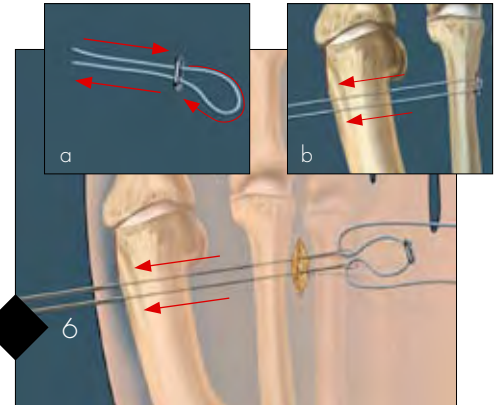
3 Incise the medial capsule, exposing the entire medial eminence. The medial eminence is removed, preserving the sesamoid groove on the plantar aspect of the 1st metatarsal.



4 The lateral second metatarsal is exposed for placement of the Mini TightRope. The first metatarsal is reduced with provisional fixation to the 2nd metatarsal. A C-arm is used to assure proper placement of the 1.1 mm tapered Suture Passing K-wire at the center of the 2nd metatarsal shaft, 2-3 mm proximal to the neck of the 2nd metatarsal. Elevate and expose 2nd metatarsal with freer elevator and small rake retractor (soft tissue) prior to K-wire insertion. Place K-wires from 2nd met through 1st met. The wires should exit just proximal to the excised medial eminence, approximately 5 mm apart. **Note – Place Suture Passing K-wires simultaneously. Do not remove or pass sutures prior to placement of both wires.* For accurate placement of the K-wires, the drill angle should be modified as shown (a).



5 With the 1st metatarsal manually reduced, position the K-wires so the tapered portions just exit the medial cortex of the 1st metatarsal. This will allow easy passage of the #2 FiberWire through the drilled holes.

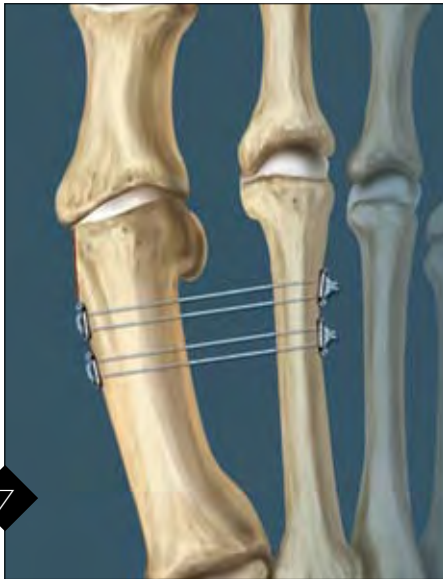
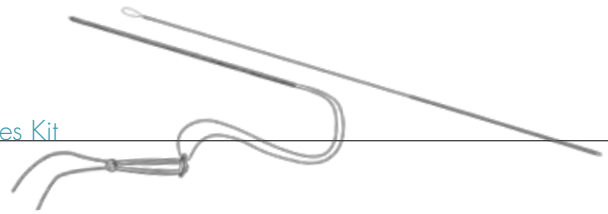


6 The distal construct should consist of two free #2 FiberWire ends threaded through an Oblong Button as shown (a).

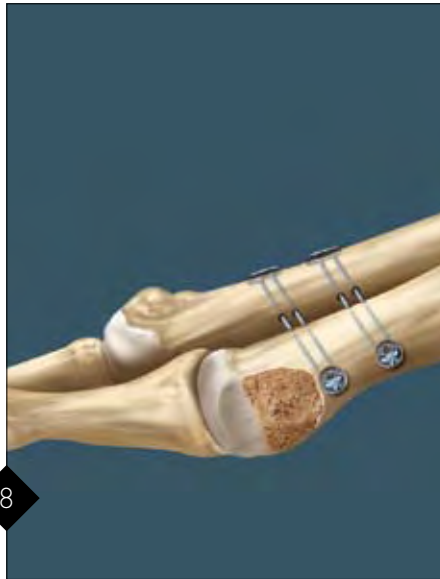Insert one free end of the #2 FiberWire through each of the exposed Nitinol wire loops on the lateral side of the 2nd metatarsal.

Pull the suture passing K-wires medially, passing the free ends through the 1.1 mm pilot holes (b).

Option: Technique as described will position suture knots on the medial 1st metatarsal. To place knots lateral to 2nd metatarsal, please review optional approach on side two of this technique.



After the suture has been passed from lateral to medial, rethread one end of the #2 FiberWire through opposite holes in the Oblong Button. (Note: If using the original AR-8911DS kit with Round Buttons, thread the buttons in the same way using opposite holes. See Fig. 8.) The first of two Mini TightRope constructs is tied down with one knot while the second construct is placed 5 - 7 mm proximal from the first construct. Repeat drilling instructions in sections 4, 5 and 6 to place second construct. The surgeon should check the IM angular correction on C-arm prior to final tightening, using three knots for closure.



Construct completed using AR-8911DS disposables kit with four Round Buttons.

Hallux Valgus Post-op Protocol

Surgery & Post-op Day 1-4

Posterior fiberglass splint
Heel weight-bearing only

Post-op Day 4 - 28 (4 weeks)

Heel weight-bearing only
Pneumatic walking boot/Cam walker
Darco bunion splint to maintain position of great toe

Post-op Day 28 (4 weeks - 6 weeks)

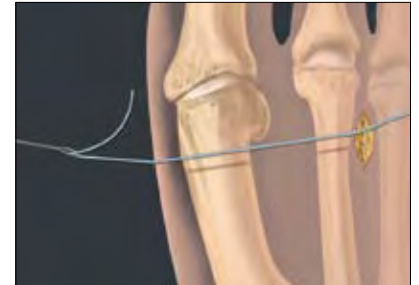Possible start in athletic shoe; only lateral or heel weight-bearing

Post-op Day 42 (6 weeks)

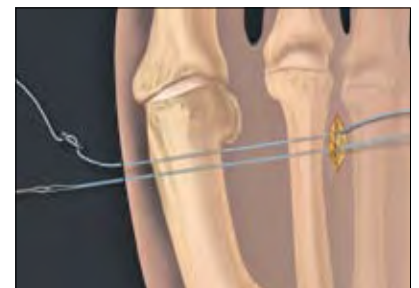Weight-bear through great toe

Note: Recovery is dependent on soft tissues scarring to hold correction and unload the device. If premature weight-bearing through medial forefoot is initiated, the 2nd metatarsal responds similarly to a stress fracture with long-term edema and mild pain.

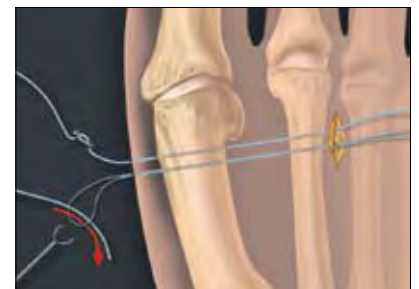
Option to step 6 - Suture knots placed lateral to 2nd metatarsal



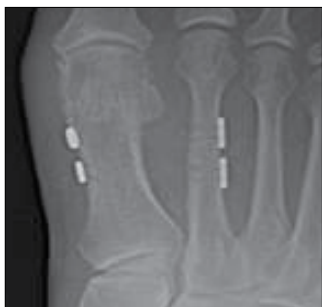Pass one limb of suture through distal hole using a Suture Passing K-wire.



Thread free end of #2 suture through both holes of the button. Using a second Suture Passing K-wire, pull through an accessory strand of 2-0 FiberWire (formed as loop) through proximal hole. The 2-0 FiberWire loop will act as a suture shuttle, pulling the #2 suture from medial to lateral.



Cut the nitinol loop portion of the passing wire. Pass the #2 FiberWire strand (about 1") through the 2-0 FiberWire loop and pull laterally. The construct can now be completed with a button and three knots lateral to the 2nd metatarsal.



Double construct complete

Mini TightRope 1.1 mm Disposables Kit

(AR-8914DS) includes:

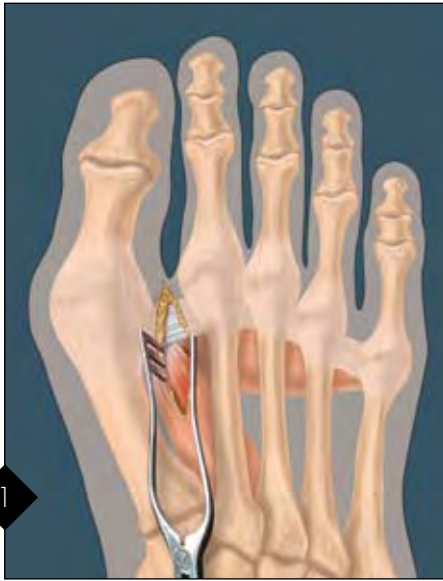
- 2.6 mm Oblong Button (4)
- FiberWire suture
- 1.1 mm Suture Passing K-wire (4)
- Skin marking pen and ruler
- Suture Passing Wire, 8" long

Accessories:

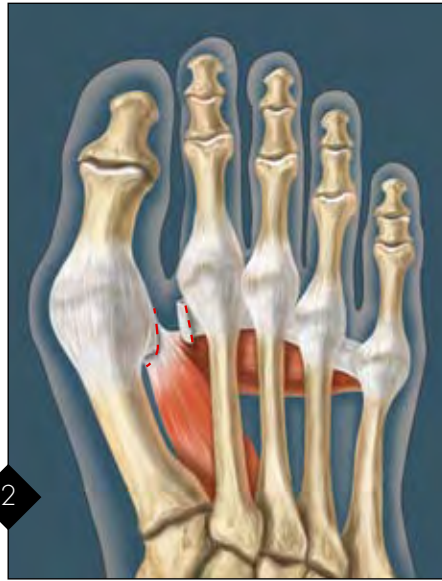- | | |
|------------------------------|----------|
| 1.1 mm Suture Passing K-wire | AR-8914K |
| 2-0 FiberWire, 38 inches | AR-7221 |
| FiberWire Scissors, small | AR-11797 |



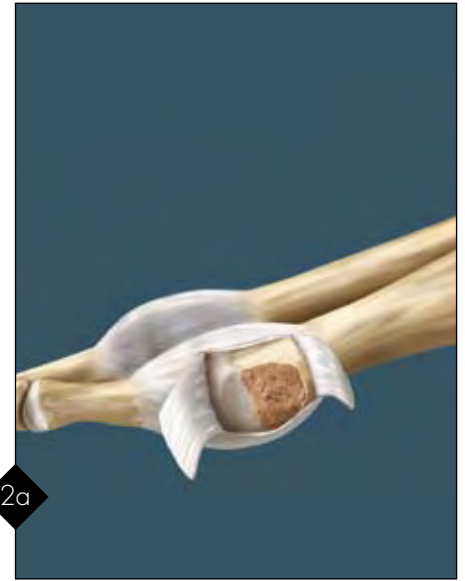
Hallux Valgus Repair 2.7 mm Drill Hole Technique



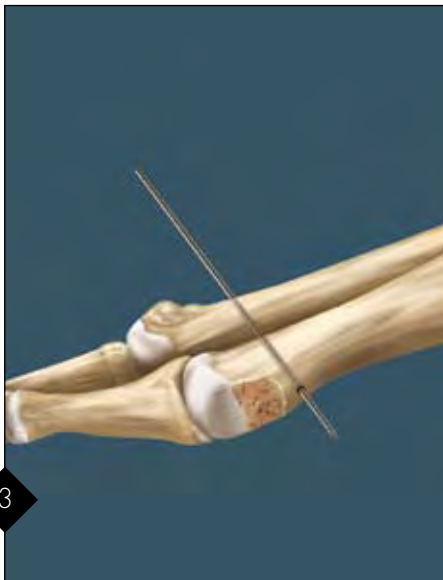
1 For the distal approach, the incision is made between the 1st and 2nd metatarsals and inner space release is performed. A medial or dorsal medial incision can also be used with appropriate soft tissue retraction.




2 To realign the fibular sesamoid, detach the adductor tendon from the base of the proximal phalanx and fibular sesamoid. Release the deep intermetatarsal ligament. If needed, free any sesamoid adhesions to the intermetatarsal ligament. Manually test for the reducibility of the angular deformity following the release of the adductor tendon, release of the lateral capsule of the first metatarsophalangeal joint and release of the intermetatarsal ligament between the 1st and 2nd metatarsals.



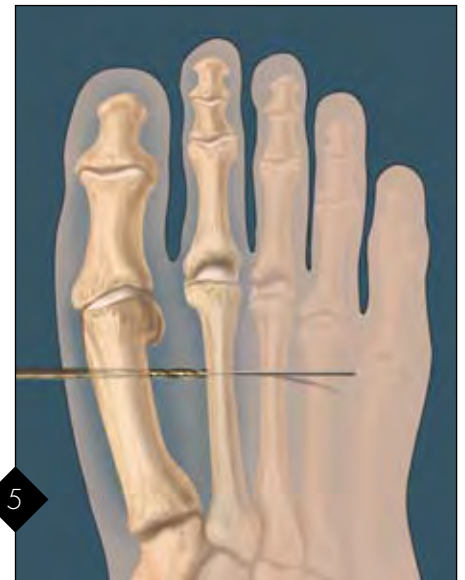2a Incise the medial capsule, exposing the entire medial eminence. Remove the medial eminence preserving the sesamoid groove on the plantar aspect of the 1st metatarsal, avoiding excessive resection of the medial eminence.



3 Using the C-arm for guidance, insert the 1.2 mm Guidewire from lateral to medial across the 2nd and then 1st metatarsals. This enhances the accuracy of bisecting the 2nd metatarsal with reference to the dorsal and plantar aspects of the metatarsal. The Guidewire should exit the 1st metatarsal just proximal to the excised medial eminence.

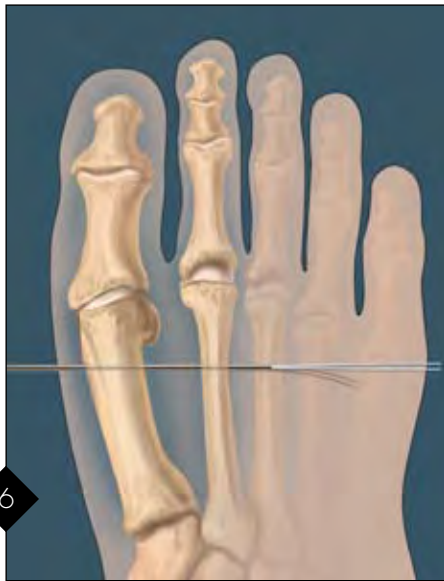


4 An adjustment in dorsal to plantar direction may assist in the accurate placement of Guidewire allowing the pin to engage the 1st metatarsal in the midpoint between its dorsal and plantar borders. The entry point on the 2nd metatarsal should be about 2-5 mm proximal to the neck of the 2nd metatarsal head.
Note: Place Guidewire while visualizing 1st - 2nd metatarsal web space. A Freer elevator can direct Guidewire penetration at 1st metatarsal midline if needed.



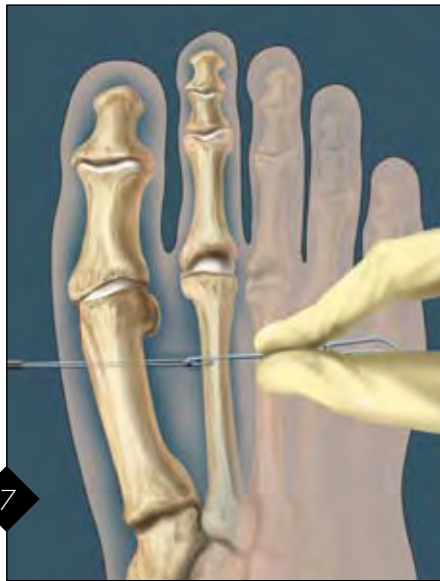5 Using the 2.7 mm Cannulated Drill Bit, drill the tunnel for the Mini TightRope over the Guidewire in a medial to lateral direction. Confirm proper placement with the C-arm.

Hallux Valgus Repair 2.7 mm Drill Hole Technique



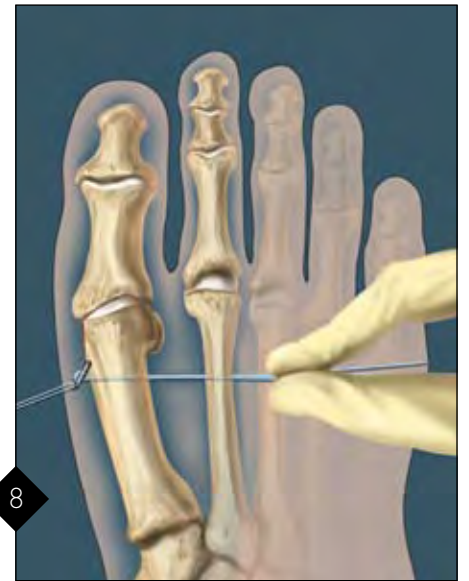6

Pass the 1.6 mm Guidepin with pull-through suture (attached to the Mini TightRope) from lateral (2nd metatarsal) to medial (1st metatarsal) and stop before the button enters the drill hole.



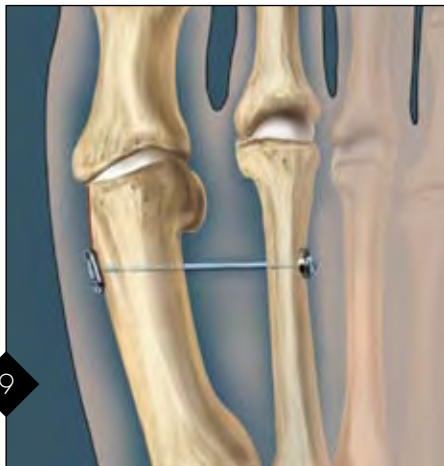7

The pull-through suture can now be advanced while the Guidepin is pulled medially. At the same time, apply lateral tension on the blue suture just behind the Oblong Button. This will help the Oblong Button to lay sideways, and pass easily through both bone tunnels.



8

The Oblong Button is flipped upon exiting the medial side of the first metatarsal cortex. Apply lateral tension on the blue suture. This will help seat the Oblong Button against the bone.



9

Repair is complete.

Note: Recovery is dependent on soft tissue scarring to hold correction and unload the device. If premature weight-bearing through medial forefoot is initiated, the 2nd metatarsal responds similarly to a stress fracture with long-term edema and mild pain.

Post-op Protocol

Surgery & Post-op Day 1-4

Posterior fiberglass splint
Heel weight-bearing only

Post-op Day 4 - 28 (4 weeks)

Heel weight-bearing only
Pneumatic walking boot/Cam walker
Darco bunion splint to maintain position of great toe

Post-op Day 28 (4 weeks - 6 weeks)

Possible start in athletic shoe; only lateral or heel weight-bearing

Post-op Day 42 (6 weeks)

Weight-bear through great toe

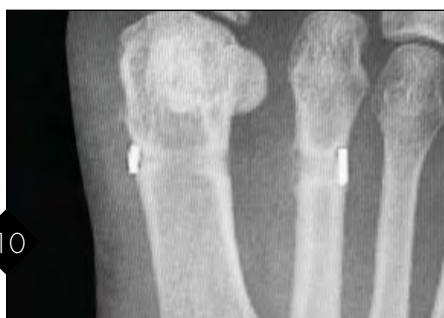The white pull-through suture is cut and removed. The surgeon should manually push the 1st metatarsal and the 2nd metatarsal together to correct the intermetatarsal angular deformity. Once fluoroscopy confirms proper positioning, the trailing Round Button is tightened down by applying gradual tension on the remaining two strands of blue suture. Tie three half-hitches and cut the suture. Any previously placed sutures incorporating the lateral capsule of the 1st metatarsal, the adductor tendon and the medial capsule of the 2nd metatarsal are tied, thus completing the repair.

Mini TightRope Disposables Kit (AR-8911DS) includes:

Canulated Drill Bit, 2.7 mm
Round Button, 5.5 mm
Oblong Button, 2.6 mm
TightRope Guide Pin, 1.6 mm
K-wire

Accessories:

Micro SutureLasso, straight	AR-8703
Micro SutureLasso, minor bend	AR-8701
FiberWire Scissors, small	AR-11797



10

X-ray showing proper placement of medial and lateral button using the 2.7 mm drill hole technique.

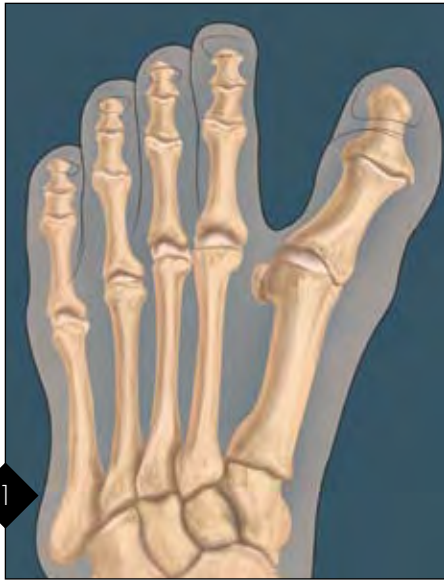


© 2008, Arthrex Inc. All rights reserved.

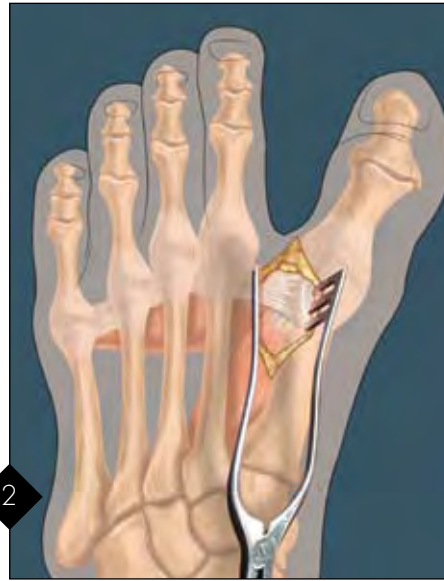LT0421A

Hallux Varus Repair

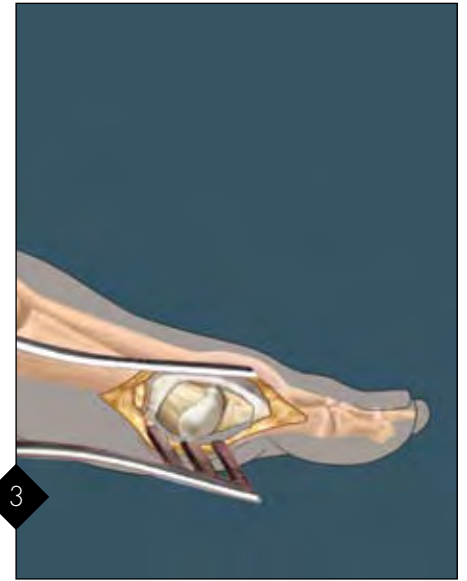Mini TightRope® Disposable Kit



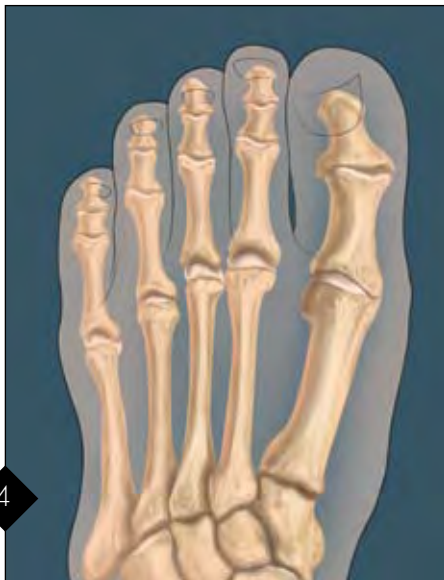Preoperative diagram demonstrating typical hallux varus deformity.



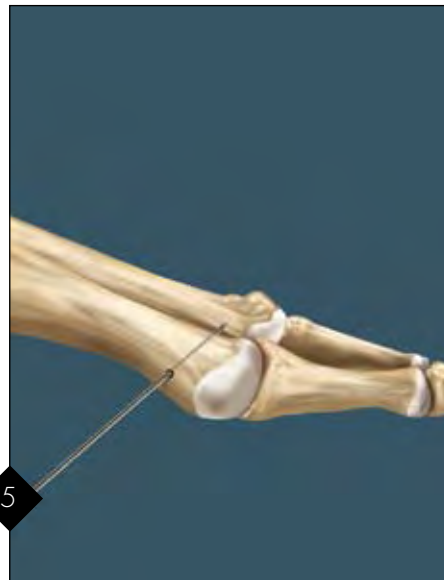
Dorsal first web space incision. A dorsal medial or medial incision can also be used with approach distraction of soft tissues. Careful dissection should be done to expose the lateral base of the proximal phalanx and neck of the first metatarsal.



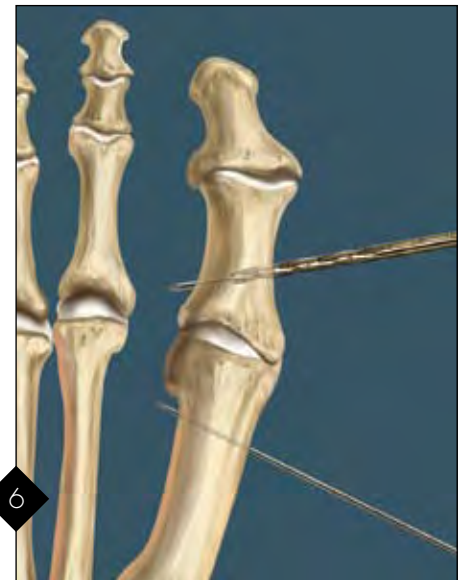
The abductor hallucis longus tendon is identified and either released or lengthened from its insertion into the proximal phalanx and tibial sesamoid. The medial capsule is incised as well.



Passive correction should now be possible without the surgeon holding the toe. Ideally, the Mini TightRope would just hold the correction obtained with the soft tissue release.



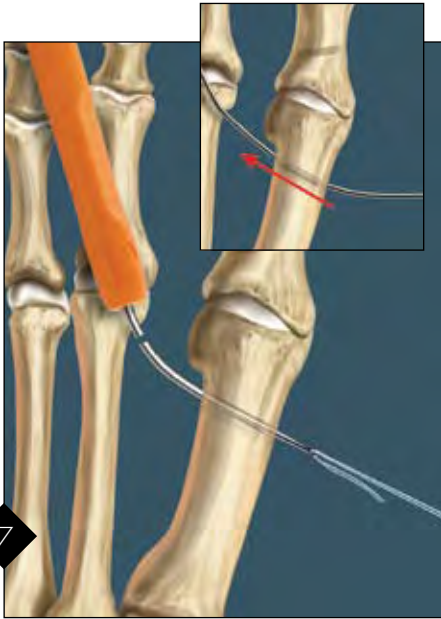

The K-wire is then placed in the medial midline of the 1st metatarsal. (Orient both K-wires so they angle obliquely 40° - 50° as shown.) Position should be checked using fluoroscopy. Midline placement of the pin should be checked visually by inspecting entry and exit points on both the medial and lateral sides of the 1st metatarsal.



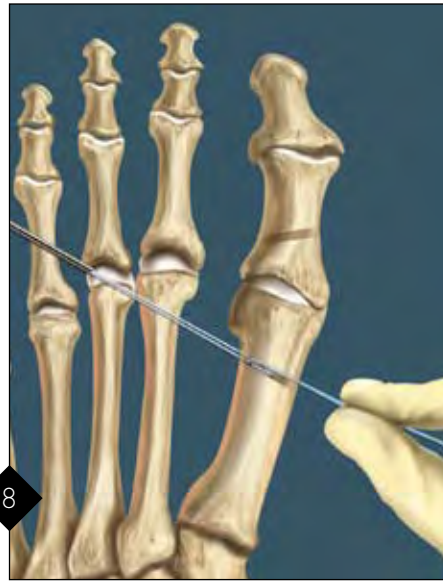Similarly, a K-wire is placed in the midline of the medial side of the proximal phalanx into the first web space. Once placement of the K-wires is complete, the 2.7 mm cannulated drill is used over each K-wire. The K-wires are then removed.

Hallux Varus Repair

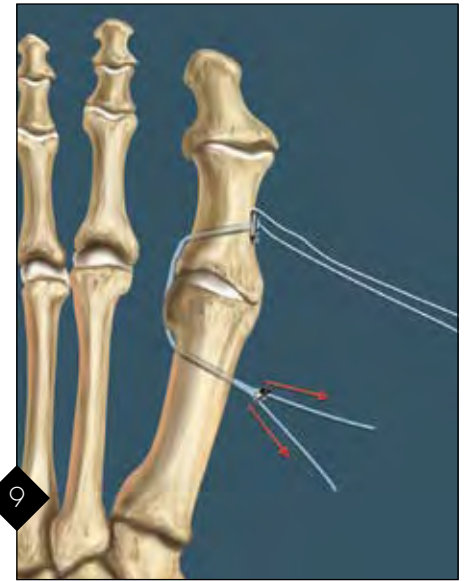
Mini TightRope Disposable Kit



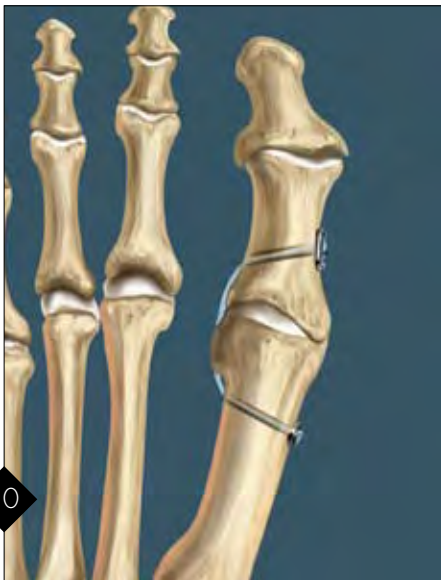7 The white traction suture is cut from the needle at the swedge point (suture and needle interface). Using the Micro SutureLasso, the white traction suture is pulled through the 1st metatarsal bone tunnel. *Option: The pull-through Guidewire can be bent slightly and passed through the 1st metatarsal bone tunnel and then through the proximal phalanx.*



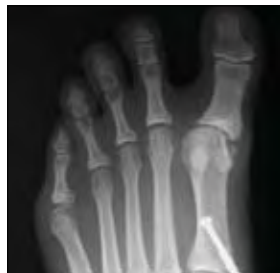8 With tension on the suture now in the first web space, and countertension on the FiberWire of the Mini TightRope, the Oblong Button can be passed into the first web space.



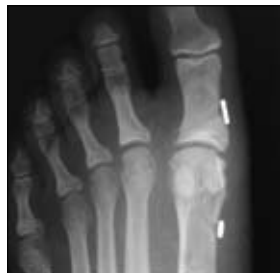9 A similar wire passing method is then used to pass the suture attached to the Oblong Button from the first web space, through the proximal phalanx, exiting the medial side of the phalanx. The white suture attached to the Oblong Button can be removed.



10 With the toe held in a reduced position, pull on the suture attached to the Round Button on the medial side of the first metatarsal. The Oblong Button will now lay flat on the proximal phalanx. Pull simultaneously on the sutures as shown to snug the round washer to the first metatarsal. It is suggested to place a small tubular structure between the small loop and the button to make fine adjustments easier. Check the tension of the suture in the web space directly. Once satisfied, tie the sutures.



Pre-op x-ray



Post-op x-ray

Post-Op Treatment: The patient's foot is placed in a spica wrap, holding the toe in slight valgus. Weight-bearing in a post-op shoe is allowed as tolerated. The spica wrap is changed weekly for six weeks. Transition to a shoe and ROM exercises are started. Patient may progress to activities as tolerated.

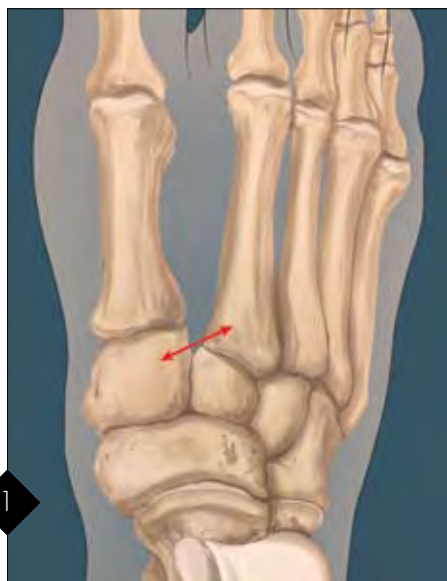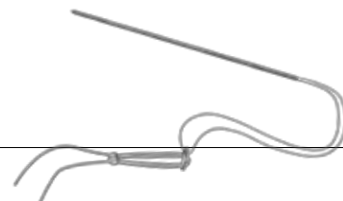
Mini TightRope Disposables Kit (AR-8911DS) includes:
 Cannulated Drill Bit, 2.7 mm
 Round Button, 5.5 mm
 Oblong Button, 2.6 mm
 TightRope Guide Pin, 1.6 mm
 K-wire

Accessories:
 Micro SutureLasso, straight AR-8703
 Micro SutureLasso, minor bend AR-8701
 FiberWire Scissors, small AR-11797

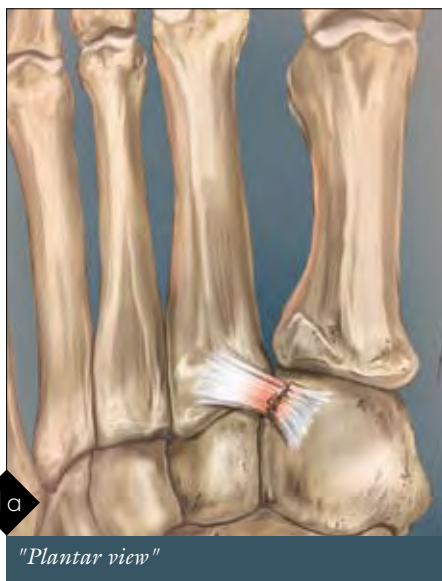

© 2008, Arthrex Inc. All rights reserved.
 LT0428A

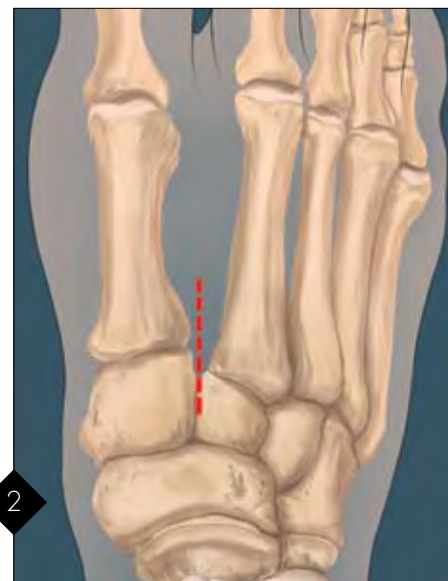Lisfranc Ligament Repair Mini TightRope® Disposables Kit



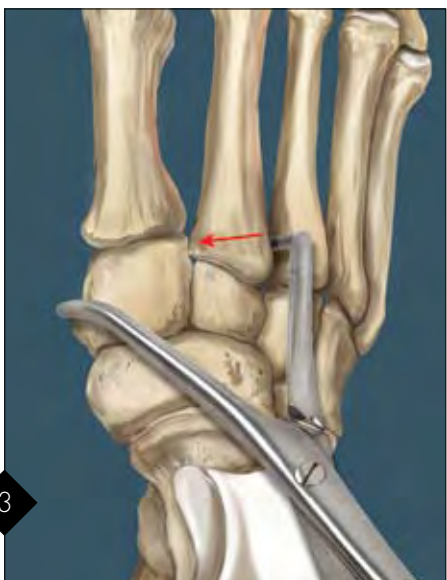1
The stability of the second metatarsal articulation with the second cuneiform is maintained by both soft tissue and bone structures. The Lisfranc ligament extends from the first cuneiform to the base of the second metatarsal, helping to maintain the anatomic orientation of the second metatarsal with the adjacent first metatarsal, first cuneiform, second cuneiform, the third metatarsal as well as the third cuneiform. Stability is further imparted by the "keystone" fitting of the second metatarsal between the first and second cuneiforms.



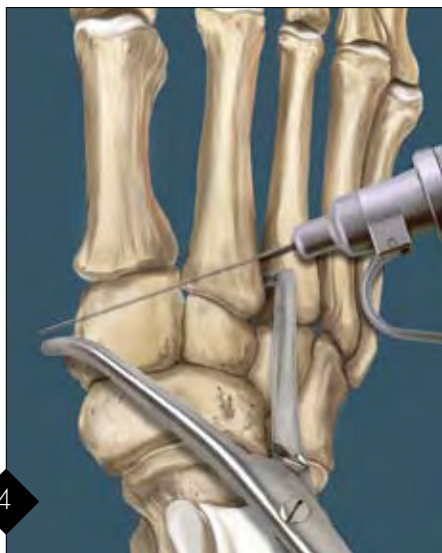
1a
"Plantar view"
An isolated rupture of the Lisfranc ligament leads to dorsal and/or lateral subluxation and displacement of the base of the second metatarsal. Fig. 1a demonstrates the inferior view of the Lisfranc joints with a tear of the Lisfranc ligament.



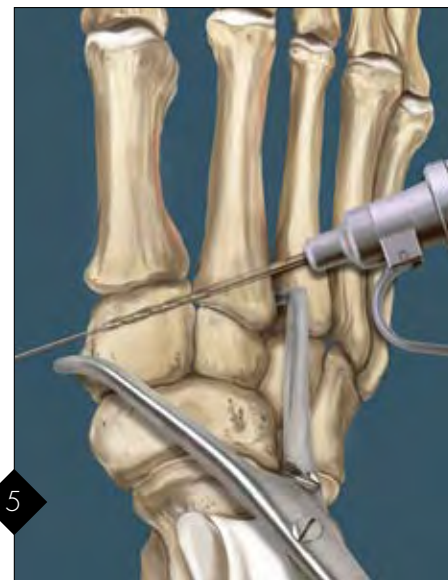2
A longitudinal, dorsal incision is centered in an area extending from the lateral border of the first metatarsal and the first cuneiform to a line over the dorsal aspect of the second metatarsal. The exact position within this zone is determined by the location of other associated fractures and injuries and the specific location of the dorsalis pedis artery.



3
The incision is continued through the dorsal retinaculum. Beware of the possible injury to the distal branch of deep peroneal nerve and the dorsalis pedis artery. After the subperiosteal dissection the second metatarsal-cuneiform joint and the space between the base of the second metatarsal and the first metatarsal are cleared of any soft tissues that might restrict anatomic reduction. A bone reduction forceps may now be utilized to secure the reduction.

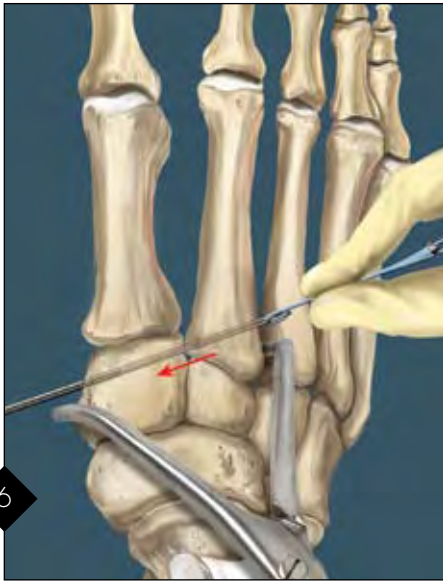



4
Fig. 4 demonstrates the insertion of the 1.1 mm K-wire from the lateral aspect of the base of the second metatarsal toward the first cuneiform exiting over the medial aspect of the foot. Exposure of the base of the second metatarsal may be facilitated by using a Hohmann Retractor around the lateral aspect of the second metatarsal. (If the lateral approach is not possible due to anatomic constraints at the lateral base of the second metatarsal, the surgeon may perform the procedure from a medial to lateral direction.)



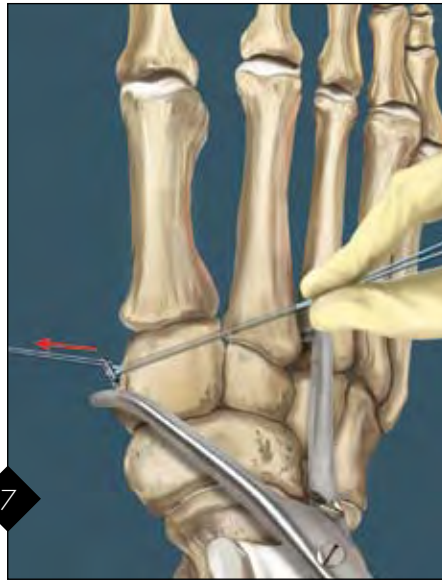
5
The bone tunnel for passage of the button is created by overdrilling the K-wire with the 2.7 mm drill bit. It is important to maintain the stability of the reduction during this portion of the procedure.

Lisfranc Ligament Repair Mini TightRope® Disposables Kit



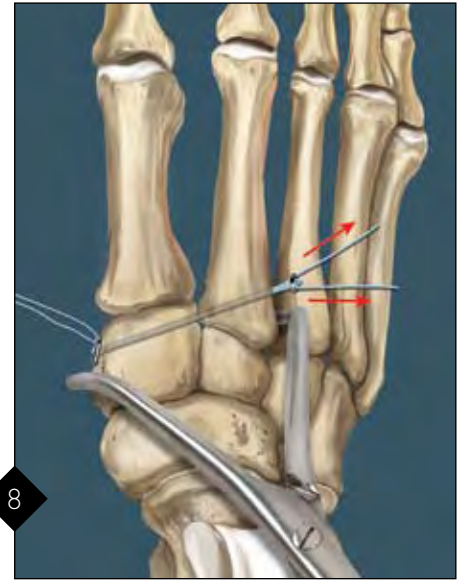
6

The leading guide pin connected to the Oblong Button is passed in a lateral to medial direction through the bone tunnel.



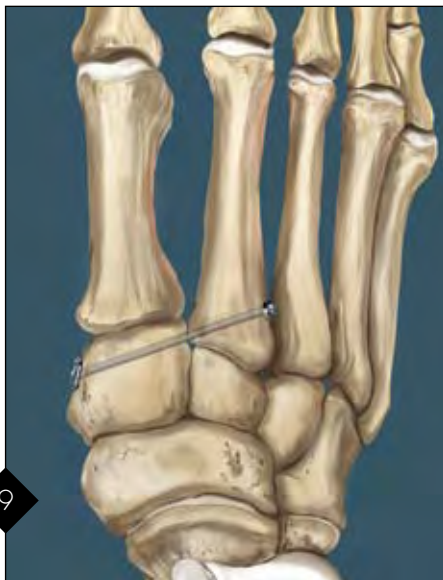7

After exiting the medial aspect of the medial cuneiform, the button is turned 90° to engage the medial cortex. Confirm that there is no soft tissue interposed between the button and the cortex of the medial (first) cuneiform.



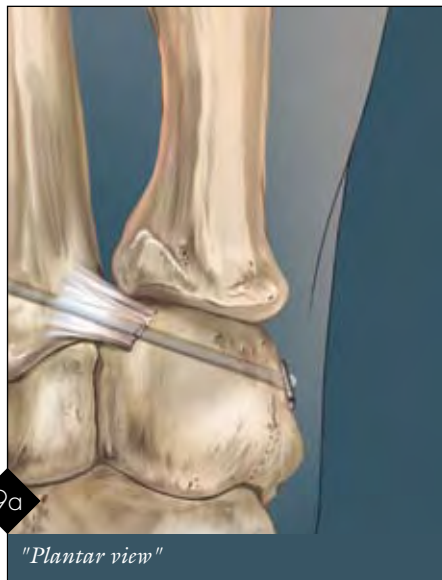8

The lateral Round Button is tightened to the cortex of the second metatarsal by simultaneously pulling (sometimes with an alternating differential pull) on the two lateral FiberWire sutures. To prevent any possible shearing, the angle between the FiberWire sutures should be no more than about 20°.



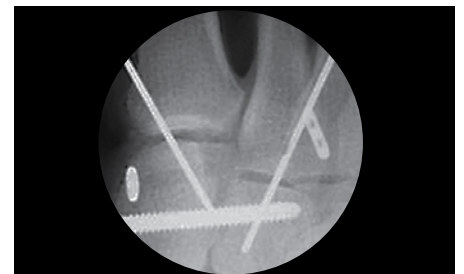
9

The adequacy of the reduction is now checked with an intraoperative film.



9a

"Plantar view"



Oblong Button placed lateral to 2nd metatarsal in this case

Mini TightRope Disposables Kit

(AR-8911DS) includes:

- Cannulated Drill Bit, 2.7 mm
- Round Button, 5.5 mm
- Oblong Button, 2.6 mm
- TightRope Guide Pin, 1.6 mm
- K-wire

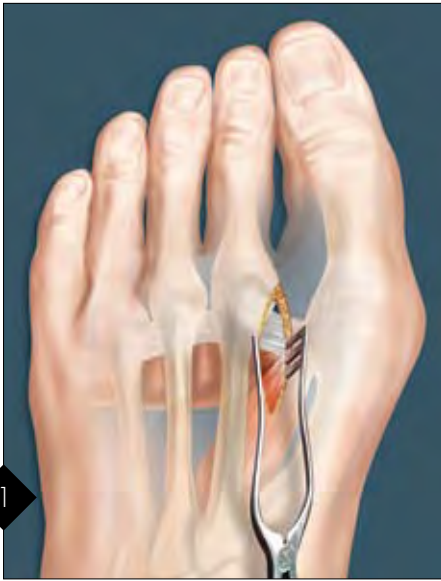Accessories:

FiberWire Scissors, small AR-11797



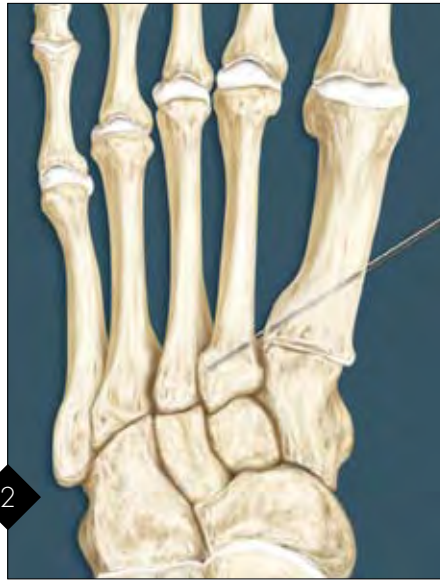© 2008, Arthrex Inc. All rights reserved.
LT0431A

Hallux Valgus Repair Mini TightRope® FT Repair Kit



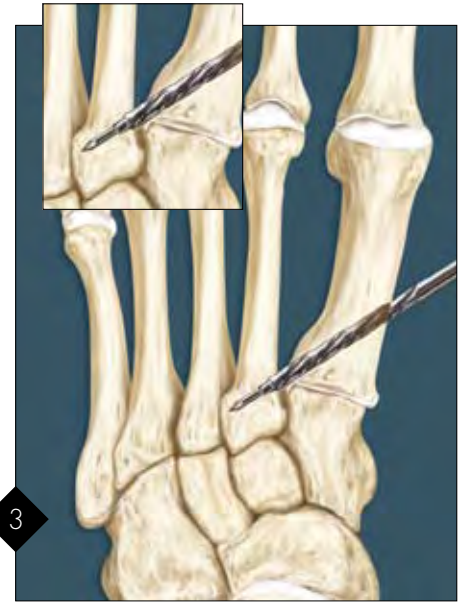1

The lateral capsular structures are released followed by the manual reduction of the 1st intermetatarsal space.



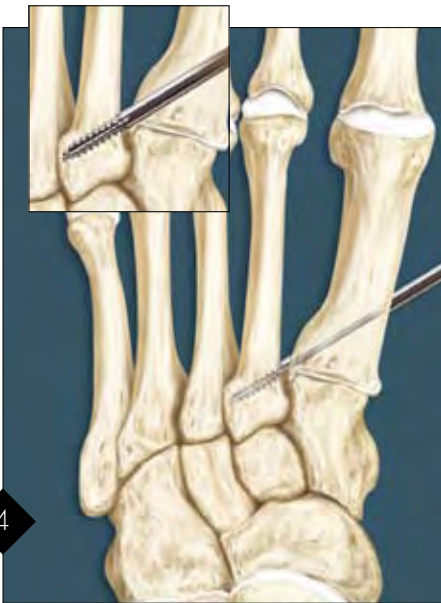
2

Insert a K-wire, starting on the medial cortex of the 1st metatarsal, at least 1.5 - 2.5 cm distal to the 1st M-C joint aiming toward the base of the 2nd metatarsal. Surgeon should utilize x-ray or C-arm to ensure proper placement of the pin.



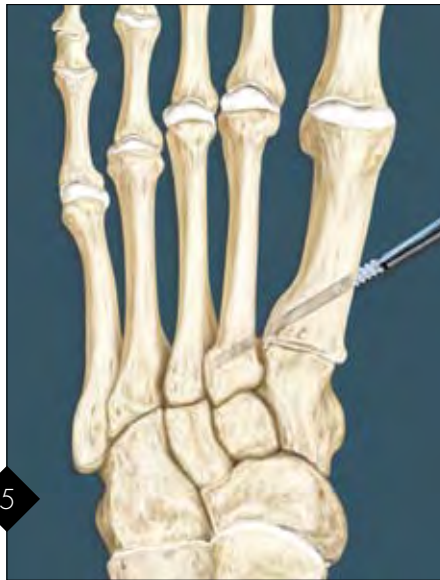3

Pass the step drill over the K-wire until the pin tip of the drill penetrates the medial cortex of the 2nd metatarsal. Confirm proper alignment with fluoroscopy. Remove the drill bit and the K-wire. Note: Do not penetrate the medial cortex of the 2nd metatarsal farther than 3 mm (length of the step drill). *Optional: For hard bone, advance the 4.5 mm drill through the 1st metatarsal and complete drilling through the 2nd metatarsal with the 2.7 mm drill.*



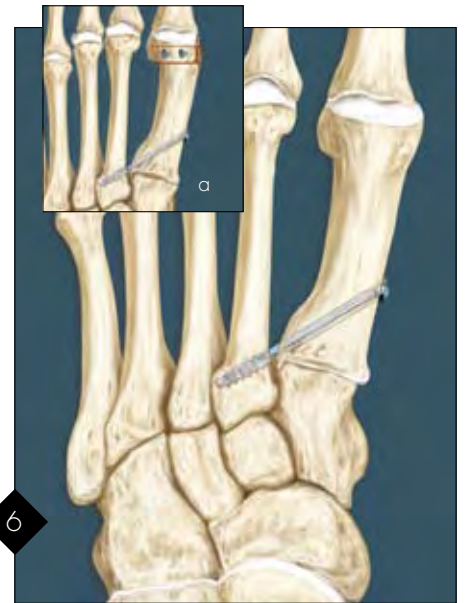4

Pass the cutting punch/tap through the 1st metatarsal and the 2nd metatarsal, making sure not to advance the instrument beyond the lateral wall of the 2nd metatarsal base. Confirm on fluoroscopy.



5

Advance the Mini TightRope FT on the driver through the 1st metatarsal and thread the anchor into the 2nd metatarsal. Confirm on fluoroscopy. Note: You can visualize the anchor only by observing the metal tip. The bioabsorbable anchor is 6 mm past the metal driver tip. *Optional: Prior to cinching down, pack the 1st metatarsal with medial eminence from the bunion.*



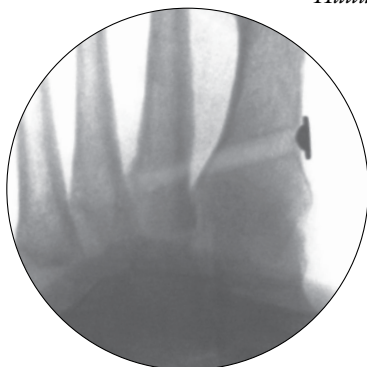6

Tighten the trailing medial button over the 1st metatarsal. Use at least three half-hitches to tie off suture and lock button in place medially. Cut the suture ends long enough to allow the knot and suture to lay down, reducing knot prominence. This procedure can also be combined with a Distal Osteotomy (Chevron shown) and secured with 3 mm QuickFix Screws (a).

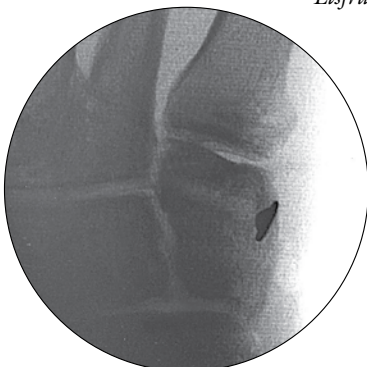
Hallux Valgus Repair Mini TightRope FT Repair Kit



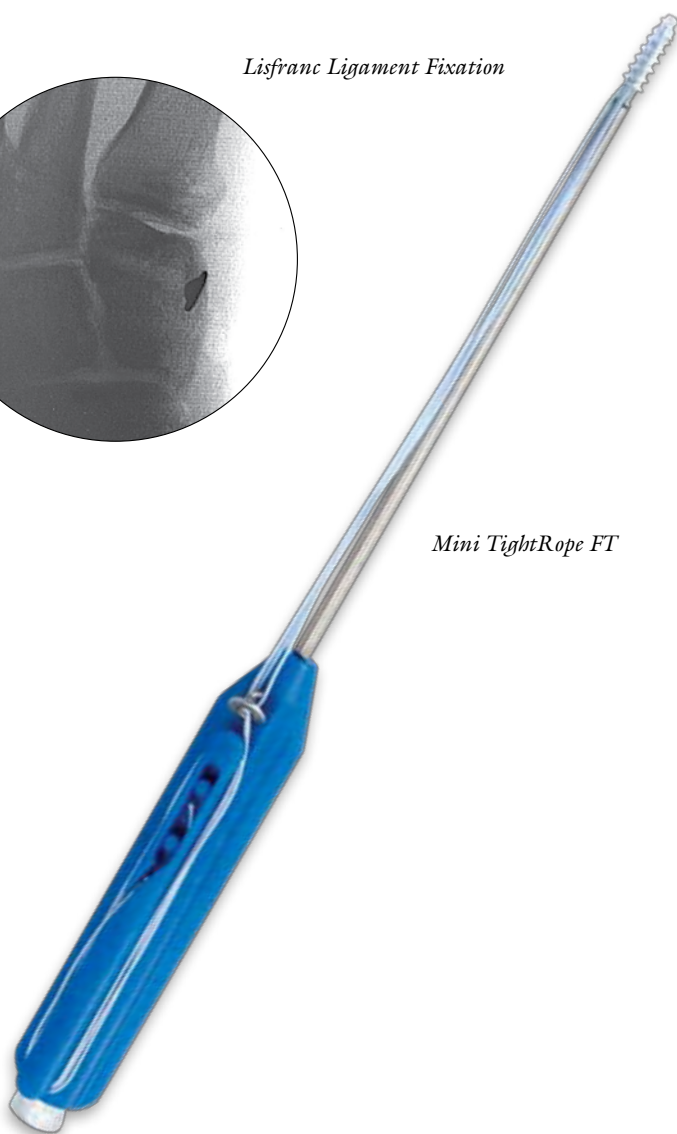Hallux Valgus Repair



Lisfranc Ligament Fixation



Mini TightRope FT



Advantages:

- Minimally invasive dorsal medial single incision
- Anchor construct stabilizes the metatarsal cuneiform joint and acts as a 'backstop' to help prevent recurrence of the deformity
- IM angle correction with or without an osteotomy. Can be used with a distal osteotomy in cases of larger IM angles or semi-rigid deformities



*Mini TightRope FT
Punch/Tap*

Ordering Information

<u>Mini TightRope FT Repair Kit (AR-8912DS), sterile, includes:</u>	
Bio-Corkscrew FT, 4.5 mm	AR-1927B-45
Cannulated Drill Bit for Mini TightRope	AR-8911DC
Mini TightRope FT Drill Bit	AR-8912DC
Driver for Mini TightRope FT	AR-8912D
Mini TightRope FT Punch/Tap, 4.5 mm	AR-8912T
Cup Button, 7.8 mm	AR-8912
Guidewire	AR-8920P



© 2008, Arthrex Inc. All rights reserved.

LT0422A

